

A Novel Algorithm for the Minimal Invasive Treatment of Choledocholithiasis

Zdravko Perko, Kanito Bilan, Zenon Pogorelić, Darko Sršen, Nikica Družijanić

Damir Kraljević, Joško Juričić, Željko Mimica, Tomislav Jurišić¹, Miroslav Bekavac-Bešlin²

University Department of Surgery, Clinical Hospital and Medical School Split, Split; ¹Department of Surgery

General Hospital Šibenik, Šibenik; ²University Department of Surgery

Clinical Hospital "Sestre milosrdnice" Zagreb, Croatia

Corresponding Author: Ass. Prof. Zdravko Perko, MD, PhD, University Department of Surgery

Clinical Hospital Split, Spinčićeva 1, 21 000 Split, Croatia

Tel: +38521556250, Fax: +38521556691, E-mail: zperko@kbsplit.hr

ABSTRACT

Background/Aims: Laparoscopic cholecystectomy is the gold standard in choledocholithiasis treatment. Currently there is no generally accepted algorithm for choledocholithiasis treatment. A few years ago suspected or diagnosed choledocholithiasis was indication for open operation if bilious stones could not be removed with therapeutic endoscopic retrograde cholangiopancreatography (ERCP). Today, advancements in laparoscopic equipment and operation technique render the possibility for laparoscopic treatment of choledocholithiasis. There are many different ways in which to treat choledocholithiasis, depending on the time of diagnosis. Due to the considerable variability in choledocholithiasis treatment, which depends in turn on many objective and subjective factors, we propose a unique diagnostic algorithm for the treatment of choledocholithiasis.

Methodology: From January 1st until December 31st 2005, at the University Department of Surgery - Split, 131 laparoscopic cholecystectomies were performed. Thirty-three patients with suspected choledocholithiasis were treated by laparoscopic intraoperative cholangiography. After positive cholangiography, thirteen laparoscopic transcystic extractions

were performed. The patients were treated in the supine position. The surgeon was positioned between the legs of the patient, the assistants on opposite sides of the patient, and the scrub nurse on the right side of the surgeon. Transcystic stone extraction was performed using a flexible choledochoscope, which was connected to the left laparoscopic monitor using Picture-in-picture system and by Nitinol tipless Dormia basket.

Results: The total number of operated patients includes 18 women and 15 men. The mean age of patients was 60.16 ± 15.36 . The mean length of operation was 86 ± 21.79 . Mean hospitalization length of patients with laparoscopic cholecystectomy was 2.45 ± 1.14 days; while mean hospitalization length of patients with stone extraction was slightly longer 2.90 ± 1.18 , ($p=0.564$).

Conclusions: Today several different possibilities approaches exist for the treatment of choledocholithiasis and it doesn't have to be treated unconditionally using endoscopic retrograde cholangiopancreatography (ERCP) and sphincterotomy before, during or after laparoscopic cholecystectomy, or by the open operation.

KEY WORDS:

Chole-
docholithiasis;
Cholelithiasis;
Laparoscopic
cholecystectomy;
Endoscopic
retrograde
cholangio-
pancreatography;
Common bile duct
exploration

ABBREVIATIONS:

Endoscopic
Retrograde
Cholangio-
pancreatography
(ERCP);
Endoscopic
Papillotomy (EP);
Intravenous
Cholangiography
(IVH);
Ultrasonography
(US);
Computerized
Tomography (CT);
Laparoscopic
Cholecystectomy
(LC);
Laparoscopic
Transcystic
Extraction (LxTC);
Intraoperative
Cholangiography
(IOCH);
Laparoscopic
Intraoperative
Cholangiography
(LxIOCH);
Laparoscopic
Choledochus
Exploration
(LcExChole)

INTRODUCTION

Laparoscopic cholecystectomy is the gold standard for the treatment of cholelithiasis. Unfortunately, today there are no standardized algorithms for choledocholithiasis treatment, despite the fact that 16% of the patients submitted to cholecystectomy have concurrent choledocholithiasis (1). Patients at greater risk for choledocholithiasis include those with elevated values of transaminases, bilirubin and alkaline phosphatase, with larger common bile duct diameter as shown in abdominal ultrasonography, those with biliar pancreatitis and obstructive icterus, or those with tiny stones. Denominated risk factors at the same time are indications for preoperative diagnostic arrangement alignment or intraoperative examination of the bilious tract (intraoperative cholangiography) (2-6).

A few years ago suspicion or diagnosis of choledocholithiasis was an indication for an open operation if

stones were not removed via therapeutic endoscopic retrograde cholangiopancreatography (ERCP) and endoscopic papillotomy (EP). Today, advancements in laparoscopic equipment and operative techniques render the possibility for laparoscopic treatment of choledocholithiasis.

Depending on the time of diagnosis, there are several treatment options for choledocholithiasis (**Figure 1**):

- 1) Preoperative diagnosed choledocholithiasis (by ERCP, contrast methods which are partly obsolete - intravenous cholangiography - IVH, uncertain ultrasonography diagnosis - US, computerized tomography - CT (**Figure 2**)).
- a) Preoperative ERCP + EP and stone extraction followed by laparoscopic cholecystectomy (LC).
- b) Synchronous LC and ERCP during laparoscopic operation.

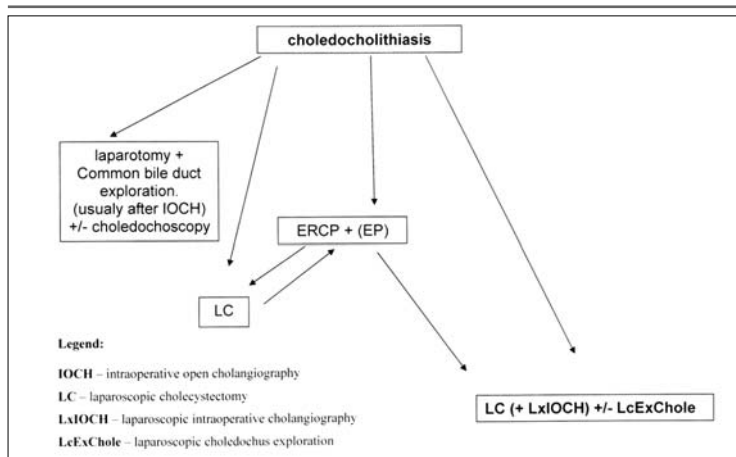
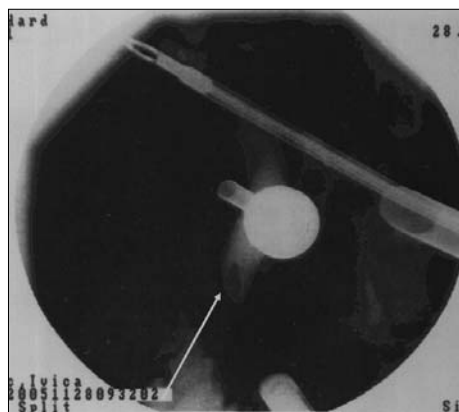


FIGURE 1 Choledocholithiasis treatment. IOCH: intraoperative open cholangiography; LC: laparoscopic cholecystectomy; LxIOCH: laparoscopic intraoperative cholangiography; LcExChole: laparoscopic choledochus exploration.

FIGURE 2 Choledocholithiasis diagnosed by CT (stone marked with arrow).

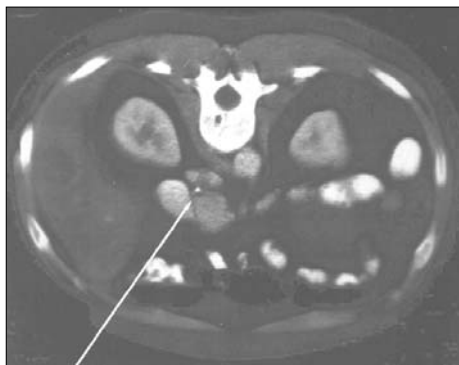

FIGURE 3 Choledocholithiasis diagnosed with intraoperative cholangiography (IOCH; stone marked with arrow).



- c) Laparoscopic extraction by transcystic (LxTC) or common bile duct approach (usually after laparoscopic intraoperative cholangiography - LxIOCH), with no preoperative ERCP or after ERCP treatment failure.
- d) Open operation (usually after open intraoperative cholangiography - IOCH).
- e) LC and postoperative ERCP treatment.
- 2) Preoperative undiagnosed choledocholithiasis - choledocholithiasis diagnosed during LC - LxIOCH (**Figure 3**).
- a) Conversion to open operation and open stone extraction.

- b) Laparoscopic extraction by transcystic or common bile duct approach (**Figure 4**).
- c) Synchronous LC and ERCP during the same operation (rendevuis technique).
- d) LC and postoperative ERCP treatment.

Because of many different approaches in choledocholithiasis treatment, which depend on many objective and subjective factors, we consider the necessity of the unique diagnosis algorithms and choledocholithiasis treatment.

METHODOLOGY

Patients were treated in the supine position. The surgeon was positioned between the legs of the patient, the assistants on opposite sides of the patient, and the scrub nurse on the right side of the surgeon. Those positions should be advised (**Figure 5**). Two laparoscopic monitors were utilized, situated next to the patient's right and left shoulder. The C-arm fluoroscopic monitor device was placed by the right monitor with the movable fluoroscopic device (Fluoroscopic C-arm unit) by the left monitor. The trocars were usually positioned for the laparoscopic cholecystectomy: the first 10-mm trocar for the laparoscope was placed supraumbilically, the second 5-mm trocar for the grasper was placed at the right mid-clavicular line, and the third 10-mm working trocar was positioned in the left mid-clavicular line. The fourth 5-mm trocar for LxIOCH and choledochoscope was placed in the right subcostal position (**Figure 5**).

Following dissection of the cystic duct and artery, the cystic artery was clipped and cut. Another clip was placed on the distal part of a cystic duct where a "T"-shaped incision was performed (7). Through this incision a narrow silicon catheter was introduced and the LxIOCH was performed using contrast (76% Urografin 7.4g/L, Schering A.G., Germany), with diascopy of the fluoroscopic device (Siemens Siremobil Compact, Germany). The fluoroscopic monitor was connected to the laparoscopic camera processor, so that a cholangiography picture could be obtained on the laparoscopic monitor (Picture-in-picture technology) (**Figure 4**). In the case of a positive LxIOCH, the transcystic extraction was performed using a flexible choledochoscope (CHF

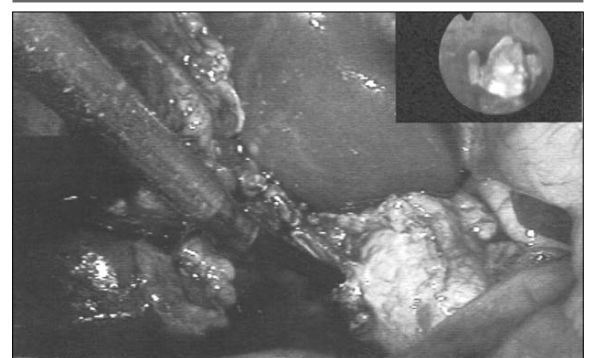


FIGURE 4 Laparoscopic transcystic choledocholithotomy - a stone exposure before extraction ("picture in picture") - choledochoscope is in the Rigid Telescopic Introducer (18).

type CB30S Olympus, Tokyo, Japan) connected to the left laparoscopic monitor using a Picture-in-picture system. After stone exposure, the stones were removed via a Nitinol tipless Dormia basket (N-Circle® Nitinol Tipless Stone Extractor, Cook, Bloomington, USA). After successful stone extraction, the cystic duct was clipped, and the cholecystectomy terminated. The operation field was drained with a 14-Ch silicone tube pulled through the right 5-mm trocar. Postoperative therapy was not different from that applied to simple laparoscopic cholecystectomies; this consisted of par-enteral rehydration on the first postoperative day (with enteral liquid food in the evening on the day of the operation), analgesics, H2 blockers and low molecular weight heparin. Antibiotics were not routinely administered, however Cephalosporin antibiotics were introduced during the operation in case of the cholecystitis or common bile duct extraction in patients older than 70 years.

RESULTS

From January 1st to December 31st 2005, at the University Department of Surgery - Split, 131 laparoscopic cholecystectomies were performed by the authors. Thirty three patients with suspected choledocholithiasis were treated by LxIOCH and laparoscopic transcystic choledochoscopy after a positive LxIOCH. Thirteen laparoscopic transcystic extractions were performed. Only one patient underwent laparoscopic transcystic stone extraction without previous IOCH due to iodine contrast substance allergy. Two patients were not able to undergo a laparoscopic operation due to the inability to perform the Dormia basket stone extraction, due to a residual falling out of the control IOCH after the extraction of stones. Two patients had a negative laparoscopic choledochoscopy (false positive LxIOCH). Eight patients underwent laparoscopic choledocholithotomy leading to a successful stone extraction.

The total number of operated patients included 94 women and 37 men. Thirty-three patients were treated by LxICOH. The medium age of the patients with choledocholithiasis was 60.16 (range 22-82; SD 15.35) years with a male to female ratio of 15:18. The mean length of operation was 86±21.79. Mean hospitalization length of patients with laparoscopic cholecystectomy was 2.45±1.14 days; while mean hospitalization length of patients with stone extraction was slightly longer 2.90±1.18 (p=0.564). From the total number of 131 operated patients, only 21 received postoperative antibiotic therapy. There were no complications. Hospital pending, recovery and working abilities were equal to the common laparoscopic cholecystectomy.

DISCUSSION

Laparoscopic cholecystectomy is the gold standard for the treatment of the gallbladder stones, but when considering the treatment of choledocholithiasis the opinions are divided. Today, no standardized algorithm for diagnostic and/or therapy procedures exists. The diagnosis and treatment of choledocholithiasis patients

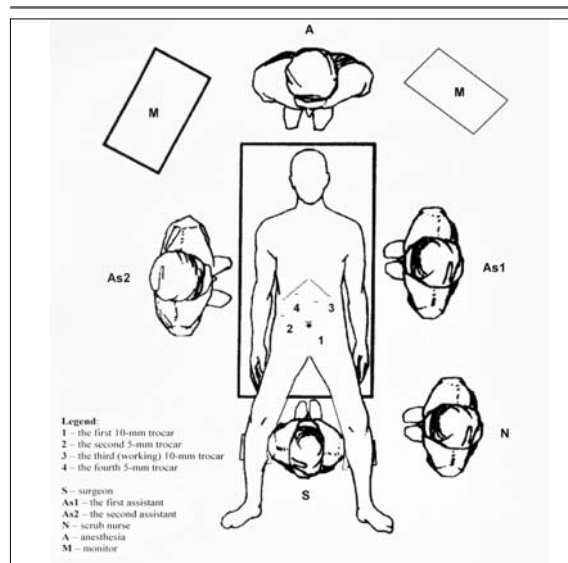


FIGURE 5 Arrangement in operation hall and placement of trocars. 1: the first 10-mm trocar; 2: the second 5-mm trocar; 3: the third (working) 10-mm trocar; 4: the fourth 5-mm trocar; S: surgeon; As1: the first assistant; As2: the second assistant; N: scrub nurse; A: anesthesia; M: monitor.

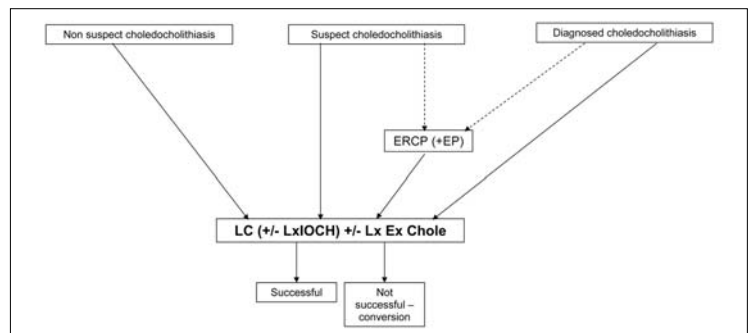


FIGURE 6 Proposal algorithm for choledocholithiasis therapy. ERCP: endoscopic retrograde cholangiopancreatoduodenography; EP: endoscopic papillotomy; LC: laparoscopic cholecystectomy; LxIOCH: laparoscopic intraoperative cholangiography; LxExChole: laparoscopic choledochus exploration.

depends on technical possibilities, hospital equipment (Radiology, Internal medicine, Surgery) and liability of the internists and surgeons as well as the patient's desire.

Endoscopic retrograde cholangiopancreatography (ERCP), considered a "non-surgical" procedure, is used in the diagnosis and treatment of choledocholithiasis, and can be performed either before, during or after the operation. For routine, nonselective preoperative choledocholithiasis, diagnostic ERCP is not recommended because of its high cost and potential complications such as bleeding, pancreatitis, perforation and cholangitis (8-10). A multicentric study in 1999 carried out by the European Society for Endoscopic Surgery conclude that ERCP is recommended for the patients with cholangitis, or impacted stones in the ampulla of common bile duct, serious biliar pancreatitis, difficult comorbidity, or a suspected common bile duct tumor (11). Conversely, ERCP is not recommended as a routine diagnostic tool in suspected choledocholithiasis (because of the possible complications) or for the younger patients. It is mentioned that the endoscopic papillotomy may invoke duodenal reflux into the common bile duct and as a consequence the tumor of the

common bile duct (10,11).

Laparoscopic intraoperative cholangiography is a simple, safe and reliable diagnostic method with a sensitivity of 83%, specificity of 95% and reliability of 94% (12). The efficiency of LxIOCH is 96%, with an average increase in interoperative time by 4.3 minutes (13). There is still no undivided attitude regarding routine or selectivity. Selective IOCH is performed based on transaminase, bilirubin and alkaline phosphatase values and result of the common bile duct diameter ultrasound measurement (4). Based on our experience it is advisable to perform LxIOCH, even after ERCP, on which occasion was tried or done the stone extraction (14). This method results in very few complications.

Laparoscopic choledochoscopy is both a diagnostic and therapeutic procedure that can be performed transcystically or through a common bile duct incision. Transcystical stone extraction is preferred with smaller numbers of stones (up to 5), smaller sizes of stones (up to 9mm in diameters), and to the width of common bile duct to a maximum of 15mm. In other cases, laparoscopic choledochotomy is advised. Efficiency of transcystic stone extraction is 85-95%. If the choledochoscopy is performed via a choledochotomy incision, the efficiency increases up to 100% (15). The common bile duct incision can be sutured with or without drainage of the common bile duct. After laparoscopic treatment of choledocholithiasis, morbidity is less than 5%. Common complications include: bleeding, biliary leakage, bilomas or abscesses, of which the frequency is less than 2% (16).

REFERENCES

- Rojas-Ortega S, Arizpe-Bravo D, Marin Lopez ER, Cesin-Shancez R, Roman GR, Gomez C:** Transcystic common bile duct exploration in the management of patients with choledocholithiasis. *J Gastrointest Surg* 2003; 7:492-496.
- Nugent N, Doyle M, Mealy K:** Low incidence of retained common bile duct stones using a selective policy of biliary imaging. *Surgeon* 2005; 3:352-356.
- Sarli L, Costi R, Gobbi S, Iusco D, Sogobba L, Roncorni L:** Scoring system to predict asymptomatic choledocholithiasis before laparoscopic cholecystectomy. *Surg Endosc* 2003; 17:1396-1403.
- Xiao-Dong S, Xiao-Yan C, Jun-Da L, Xiu-Jun C, Yi-Ping M, Jin-Min W:** Prospective study of scoring system in selective intraoperative cholangiography during laparoscopic cholecystectomy. *World J Gastroenterology* 2003; 9:865-867.
- Bekavac-Bešlin M, Mijić A, Supanc V, Hochstadter H, Kuna T, Halkić N, Perić M:** Laparoscopic cholecystectomy and perioperative ERCP. *Hepatogastroenterology* 2000; 47:1221-1222.
- Filipović J, Bekavac-Bešlin M, Virović L, Supanc V, Zovak M, Hrabar D, Družić N:** Minimally invasive treatment of causes and complications of biliary pancreatitis. *Hepatogastroenterology* 2005; 52:1364-1367.
- Jurišić T:** Simplified technique of laparoscopic common bile duct exploration. 11th EAES Congress Glasgow, Abstract book O171. 2003; 77.
- Erickson RA, Carlson B:** The role of endoscopic retrograde cholangiopancreatography in patients with laparoscopic cholecystectomies. *Gastroenterology* 1995; 109:252-263.
- Coppola R, Riccioni ME, Ciletti S, Cosentino L, Cocco C, Magistrelli P, Picciocchi A:** Analysis of complications of endoscopic sphincterotomy for biliary stones in a consecutive series of 546 patients. *Surg Endosc* 1997; 11:129-132.
- Freeman ML, Nelson DB, Sherman S:** Complications of endoscopic biliary sphincterotomy. *N Engl J Med* 1996; 335:909-918.
- Cuscheri A, Lezoche E, Morino M:** EAES multicenter prospective randomized trial comparing two-stage versus single-stage management of patients with gallstone disease and ductal calculi. *Surg Endosc* 2003; 13:952-957.
- Greig JD, John TG, Mahadaven M, Garden OJ:** Laparoscopic ultrasonography. In the evaluation of the biliary tree during laparoscopic cholecystectomy. *Br J Surg* 1994; 81:1202-1206.
- Wenner DE, Whitwam P, Turner D, Kennedy K, Hashmi S:** Actual time required for dynamic fluoroscopic intraoperative cholangiography. *J SLS* 2005; 9:174-177.
- Perko Z, Družić N, Kraljević D, Jurišić J, Bilan K, Krnić D, Sršen D, Petričević A:** Laparoscopic surgery at Clinical hospital Split - Krizine: A first year. Eight Slovenian congress of endoscopic surgery with international participation. Portorož, 8th-10th may 2005. *Endoscopic Rev* 2005; 10:55.
- Tokumura H, Umezawa A, Cao H, Sakamoto N, Imaoka Y, Ouchi A, Yamamoto K:** Laparoscopic management of common bile duct stones: transcystic approach and choledochotomy. *J Hepatobiliary Pancreat Surg* 2002; 9:206.
- Wood T, Macfadyen BV:** Diagnostic and therapeutic choledochoscopy. *Semin Laparosc Surg* 2000; 7:288-294.
- Collins C, Maguire D, Ireland A, Fitzgerald E, O'Sullivan G:** A prospective study of common bile duct calculi in patients undergoing laparoscopic cholecystectomy: natural history of choledocholithiasis revisited. *Ann Surg* 2004; 239:28-33.
- Jurišić T:** Modified technique of laparoscopic transcystic common bile duct exploration. 12th EAES Congress Barcelona, Abstract book O116. 2004; 45.

Despite our efforts to diagnose and cure choledocholithiasis, 5% of patients remain asymptomatic with unrecognized choledocholithiasis. These patients are not usually submitted for preoperational or intraoperative diagnostics, except for a routine LxIOCH. But only about 15% of the patients can suffer later and than ERCP is the method of choice (17).

Based on our group experience, the experience of our hospital, and the literature data, we recommend the follow algorithm for choledocholithiasis treatment (**Figure 6**):

- 1) Unsuspected choledocholithiasis - laparoscopic cholecystectomy
- 2) Suspected or verified cholelithiasis.
 - a) Older patients; large number of stones suspected; common bile duct tumor suspected - ERCP + EP, laparoscopic cholecystectomy with IOCH - in case of positive finding: laparoscopic extraction (transcystical or by choledochotomy); if the laparoscopic operation is not possible - conversion to the open procedure.
 - b) Younger patients: laparoscopic cholecystectomy with IOCH - in case of positive find: laparoscopic choledocholithotomy (transcystical or by choledochotomy); if the laparoscopic operation is not possible - conversion to the open procedure.

To conclude, there are many possibilities for the laparoscopic treatment of choledocholithiasis and the use of both ERCP and sphincterotomy either before, during or after laparoscopic cholecystectomy, or open operation, need not be the only options.